

Magnetic Resonance Spectroscopy Outperforms Conventional MRI in Diagnosing Brain Tumors: A Comparative Analysis

Muhammad Aneeqe Haider¹, Saram Javed², Murad Ali³, Muhammad Awais⁴, Sadia Javeed⁵

^{1,2,3,4}BS Medical imaging technology Riphah International

University Faisalabad campus (Riphah college of rehabilitation sciences)

⁵ Department of Medical imaging technology Riphah International

University Faisalabad campus

Corresponding Author/ Research Supervisor: Sadia Javeed

⁵ Department of Medical imaging technology Riphah International university Faisalabad campus

Email: sadiarana2529@gmail.com

Received: 28 July 2023

Accepted: 20 October 2023,

Online : 15 Feb 2024

Abstract

Background: Despite several revolutionary advances in imaging technology, physicians are still unable to obtain findings that are 100 percent reliable. A number of limitations have been noted for imaging approaches.

Objective: The aim of this study was to compare the diagnostic accuracy of magnetic resonance spectroscopy with conventional magnetic resonance imaging for brain tumors.

Study Design: A Comparative study

Place and duration of study. The Department Of Medical Imaging Technology Riphah International University Faisalabad Campus From 05-June 2023 To 05-Dec-2023

Methodology This study was carried out at the Department of Medical imaging technology Riphah International university Faisalabad campus from 05-June 2023 To 05-Dec-2023 following receiving permission from the institute's ethics committee. The study comprised 154 people, both male and female, who had a clinical suspicion of having a brain tumor. Patients between the ages of 20 and 65 who had symptoms and signs suggestive of brain tumors or had nonspecific results from CT and MRI scans were the participants in this study. The technique used was MR spectroscopy. The collected data were entered into SPSS v23.0, and frequency and percentage were reported for gender, positive MRI and MRS results, and histology, along with a 95% confidence interval.

Results; A total of 154 individuals were studied. The most prevalent age group was 50 years or above 78(50.6%) . Histopathology of 52 (33.7%) negative and 102 (66.2%) patients were tested positive for MR Spectroscopy. The findings of MR Spectroscopy were compared to conventional MRI alone, and with histology maintained as the gold standard, it was discovered that the sensitivity was 90.0% & specificity of 97.0% were at a higher diagnostic level. The results of the MRI accuracy comparison with the conventional histopathological results were 75% sensitivity, 83% specificity The MRS method has 90.0% and sensitivity 97%.

Conclusion

Thus, the study found that all of the diagnostics measures with p-values <0.001, MRS considerably enhances brain tumor characterization when compared to conventional MRI

Keywords: Diagnostic accuracy, Magnetic resonance spectroscopy, Conventional MRI, Brain tumors

Authors Contribution

MAH. Concept & Design of Study and **SJ.** Drafting, **MA, MA.** Data Analysis, and Critically Review, **SJ.** Final Approval of version

Citation: Muhammad Aneeqe Haider, Saram Javed, Murad Ali, Muhammad Awais, & Sadia Javeed. (2024). Magnetic Resonance Spectroscopy Outperforms Conventional MRI in Diagnosing Brain Tumors: A Comparative Analysis. Pakistan Journal of Advances in Medicine and Medical Research, 1(02), 75–80. <https://doi.org/10.69837/pjammr.v1i02.22>

Introduction

Intracranial tumors, first of neuroectodermal or secondarily from other sites, are enigmatic clinically because of the varying manifestation and clinical presentation that could mimic a wide variety of CNS disorders. According to recent data, intracranial neoplasms are primary brain tumors which account for 51% of all intracranial lesions with incidence rate of 18.71/100 000 population in 2011 [1]. T1-weighted MRI is the gold standard in the primary diagnosis of brain tumors because it yields detailed morphologic information. However, there is a tendency for these markers to fail in differentiating between tumor types and grades potentially bringing about diagnostic uncertainty [2]. The limitations place with MRI have provoked practitioners into evaluating other imaging modalities which holds promises over MRI such as magnetic resonance spectroscopy (MRS). MRS is a very effective in determining the pathophysiologic nature of brain tissue and therefore it serves a biochemical interest besides anatomical information that you can get from MRI. [3]. This technique can be especially useful for distinguishing between keratinocyte carcinoma and melanoma and for assessing tumour metabolism and response to the therapy [4]. In view of these concerns, there is a concern over the reliability of diagnostic conclusions based on imaging. For example, the first generation MRI does not allow for the differentiation of calcifications and hemorrhages, and therefore making the correct diagnosis is rare [5]. MRS in contrast positions the detection of metabolism changes at molecular level and hence diagnoses of diverse types of cerebral lesion are precise [6]. This research seeks to establish whether MRS has a higher accuracy than conventional MRI in detecting brain tumours based on clinical suspicion, against histopathological results.

Therefore, through a comparison of sensitivity, specificity, positive predictive value (PPV), and negative predictive value (NPV), this research aims to develop if MRS can enhance the diagnostic results of brain tumor patients by a significant margin [7]. The evidence could help in minimizing the biopsy operations making them less invasive thus enhance on the care and management of the patients [8].

Methodology

This cross-sectional study was performed from November 2023 to April 2024 in the Department of Medical Imaging Technology, Riphah International University, Faisalabad Campus, Pakistan after taking the permission of ethical committee. In all, 154 subjects with clinical suspicion of brain tumors between 20 and 65 years of age were included in the analysis. Subject participants consisted of patients from the emergency wards, outdoor and indoor clinics respectively. The exclusion criteria were as follows: a life expectancy of less than 3 years; prior tumor history; heart pacemaker; contraindication to MRI. Data was collected using both signed Performa on a bilingual level. MRI investigations were done on General Electric 1. T Magnetic resonance imaging (MRI) sequences: T1 axial, T2 axial, T2 sagittal, FLAIR coronal, and post-contrast. MRS was performed using a single voxel method with point-resolved spectroscopy (PRESS), set at TE/ TR = 135/1500. Data analysis was done using the Statistical Package for the Social Sciences (SPSS Inc. , Chicago, Illinois, USA) version 23. Figures recording frequencies, percentages, sensitivity, specificity, PPV, NPV, and accuracy.

Results

A total of 154 individuals were studied. The most prevalent age group was 50 years or above 78(50.6), followed by age group 36 to 50 years 42(27.27%) and 20 to 35 years respectively (table 1). Out of all the participants males were 87(56.49%) and females were 67(43.5%) as shown in **figure 1**. Histopathology of 52 (33.7%) negative and 102 (66.2%) patients were tested positive for MR Spectroscopy. When conventional MRI was compared to histopathology and contrast, the results showed that MRI's sensitivity was 75.0% and its specificity was 83.0%.When MR Spectroscopy findings were compared to conventional MRI alone, it was discovered that the sensitivity of 90.0% & specificity of 97.0% of the test were more diagnostically sound when histopathology was used as the gold standard. 98.8% was the PPV and 82.3% was the NPV. It was shown that MRS had a 92. % diagnostic accuracy rate. The findings of MR Spectroscopy were compared to conventional MRI alone, and with histology maintained as the gold standard, it was discovered that the sensitivity was 90.0% & specificity of 97.0% were at a higher diagnostic level. There was an 82% NPV and a 98% PPV. A documented 92 % of diagnoses were made using MRS.

MRI accuracy compared to traditional histopathological results: 77% accuracy, 75% sensitivity, 83% specificity, 90% positive prediction, 62% negative prediction, and 67% prevalence. A comparison of MRS and Histopathology showed 46 grade 1 and 48 grade 2 malignancies. All 52 remaining

cases were negative. Kappa statistics between MRS and histology were 0.921 (p-value < 0.001), and 95% of patients had matched grades. Compared to Histopathology reports, MRS offers 90.0% sensitivity, 97% specificity, 98% positive predictive value, 82% prediction of negative outcomes, 92% accuracy, and 67% prevalence. 49 grade 1 and 53 grade 2 gliomas were histopathological graded. Of the 75 (49.3%) patients with equivalent MRI grades, 16 (21.0%) had negative malignancy results shows in Table 1 to 3

Table 2: MRI contrast with reports on Histopathology

Tumor on brain (MRI)	Tumor on brain on histopathology		Value of P
	Yes	NO	
Yes	75	10	Less than 0.001
No	27	42	
Total	102	52	

Table 3: MRS contrast with reports on Histopathology

Tumor on brain (MRs)	Tumor on brain on histopathology		Value of P
	Yes	NO	
Yes	90	3	Less than 0.001
No	12	49	
Total	102	52	

Figure 1: Gender Wise Distribution

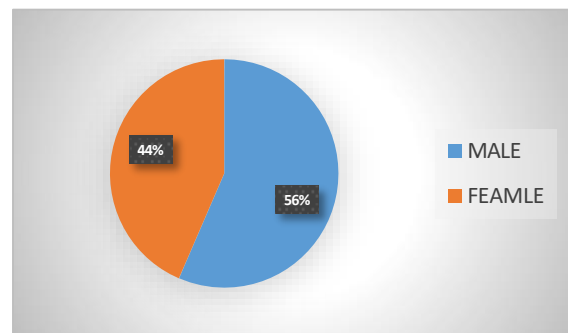


Table 1 Demographic characters

Age wise distribution	N (%)
20 to 35	34(22%)
36 to 50	42(27.27%)
50 or above	78(50.6)
Gender	
Male	87(56.49%)
Female	67(43.5%)

Discussion

This research establishes that MRS improves the diagnostic precision of brain tumor over plain MRI. The results of the present study are consistent with the earlier findings, suggesting that use of MRS yields higher sensitivity and specificity in identifying the brain lesion. Initial evaluation of brain tumor has been largely accomplished with standard MRI because of the superior anatomic information content in comparison with other imaging modalities. However, there are disadvantages in using it, especially in identifying various type of tumors and their respective grades. For example, an article by Upadhyay and Waldman stated that about conventional MRI, it is useful for initial assessments; however, it lacks the ability to characterize tumors with a significant degree of certainty [9]. This limitation provides the rationale for developing other imaging modalities such as MRS that provide Metabolite information about tumor metabolism. MRS identifies changes in biochemistry at the molecular level, which gives a chemical signature of the brain lesion. This biochemical aspect augments the detailed structural information provided by T1- and T2-weighted MRI scans into a more holistic clinical setting. In separate studies, Horská and Barker showed the increased application of MRS in differentiating between benign and malignant mass and in evaluating the response to treatment [10]. The results of the present work support these findings, illustrating that MRS enhances the diagnostic accuracy through having sensitivity and specificity of 90.0% and 97.0% respectively. Another study shows that MRS has been found to be diagnostically superior

Shown that additional MRS to the conventional MRI improves the diagnostic yield from 55% to 70% for mass lesions [11]. Similarly, Sibtain et al. also observed that with help of MRS, the tumor types could be differentiated properly which is critical in deciding on the correct line of treatment [12]. These previous findings concur with our current investigation of MRS that indicates it provides greater diagnostic accuracy over conventional MRI alone. However, the prospect of employing MRS to potentially replace invasive biopsy procedures is one of the most remarkable features. The traditional method of confirmation, which often involves histopathological examination, has some risk associated with it, such as surgical intervention[13].based on the experience of using MRS for diagnostics, it is possible to state that through accurate and non-invasive assessment of the state of certain organs and tissues, it is possible to avoid or reduce these risks. Mahmud et al mentioned Mri specificity and sensitivity as 84% and 75% respectively which is rather close to our mri findings but still lower in comparison to the mrs results we have in our study. MRS not only helps in the identification of tumors but also in grading, as from the chemical profile provided in the study. According to Lord et al. , conventional MRI provided a specificity of 65.0 % and the negative predictive value of 44.0 %, whereas the figures concerning MRS were considerably worse. Our study shows that overall, MRS is more specific (97%) and has a higher NPV (82%) compared to CT and MRI making it a better tool to use in diagnosing brain tumour. Our results are in concordance with the previously published studies which evidently validate the reliability of MRS as an

advanced diagnostic technology. For instance, Jesrani et al. , who also compared the effectiveness of MRS with the gold standard, achieved a sensitivity of 87.5% and specificity of 93.3%, which is quite similar to our findings [14]. Similarly, Alam et al. and, Amin et al. illustrated high diagnostic accuracy of MRS with sensitivity and specificity rates that are in accordance with our findings [15,16]. Lastly, as evident from the above comparative analysis, it is possible to substantiate superiority of MRS for diagnosing brain tumors as compared to conventional MRI. The improvements made to the sensitivity, specificity and the overall diagnostic capability of MRS are some of the benefits that advocate for the routine use of the technique in studying brain tumours. In addition to enhancing diagnostic certainty, this development may potentially help minimize the utilization of invasive methods in patient diagnosis, which would be advantageous to patient care and treatment[17].

Conclusion

The study found that all of the diagnostics measures with p-values <0.001, of magnetic resonance spectroscopy considerably enhances brain tumor characterization when compared to conventional MRI.

Disclaimer: Nil

Conflict of Interest: There is no conflict of interest.

Funding Disclosure: Nil

References

1. Ostrom,Q.T.,Barnholtz-Sloan, J.S.J.C.N. & Reports, N. 2011. Current state of our knowledge on brain tumor epidemiology. 11, 329-335.
2. Neugut, A. I., Sackstein, P., Hillyer, G.C., Jacobson, J.S., Bruce, J., Lassman, A. B. & Stieg, P. A. 2019. Magnetic Resonance Imaging-Based Screening for

Asymptomatic Brain Tumors: A Review. The oncologist, 24, 375-384.

3. Zulfiqar, M., Dumrongpisutikul, N., Intrapromkul, J. & Yousem, D. M.J.A. J. O. N. 2012. Detection of intratumoral calcification in oligodendrogliomas by susceptibility-weighted MR imaging. 33, 858-864.

4. Chen, W., Zhu, W., Kovanlikaya, I., Kovanlikaya, A., Liu, T., Wang, S., Salustri, C. & Wang, Y. J.R.2014.Intracranial calcifications and hemorrhages: characterization with quantitative susceptibility mapping. 270,496

5. Horská, A. & Barker, P. B. J. N. C. 2010. Imaging of brain tumors: MR spectroscopy and metabolic imaging. 20, 293-310

6. Dhillon, P. K., Mathur, P., Nandakumar, A., Fitzmaurice, C., Kumar, G. A., Mehrotra, R., Shukla, D., Rath, G., Gupta, P.C. & Swaminathan, R. J. T. L. O. 2018. The burden of cancers and their variations across the states of India: the Global Burden of Disease Study 1990–2016. 19, 1289-1306

7. Upadhyay, N. & Waldman, A. J.T.B.J.O R. 2011. Conventional MRI evaluation of gliomas. 84, S107-S111

8. Möller-Hartmann, W., Herminghaus, S., Krings,T.,Marquardt, G., Lanfermann, H., Pilatus, U. & Zanella, F. J. N. 2002. Clinical application of proton magnetic resonance spectroscopy in the diagnosis of intracranial mass lesions. 44, 371-381

9. Sibtain,N.,Howe,F.& Saunders, D. J. C R. 2007.The clinical value of proton magnetic resonance spectroscopy in adult brain tumors. 62, 109-119

10. Lord,M.L.,Chettle, D.R., Gräfe, J.L., Noseworthy, M.D. & Mcneill, F. E. J. R. 2018. Observed deposition of gadolinium in bone using a new noninvasive in vivo biomedical device: results of a small pilot feasibility study. 287, 96-103

11. Rafique, Z. , Awan, M. W., Iqbal, S., Usmani, N. N., Kamal, M. M., Arshad, W., Ahmad, M., Mumtaz, H., Ahmad, S. & Hasan, M. J. C. 2019.

12. Musawar, S., Shaukat, A., Manzoor, A. & Manzoor, I. J. T. P. M. J. 2019. Diagnostic accuracy of magnetic resonance spectroscopy (MRS) for diagnosis of focal brain lesions taking histopathology as gold standard. 29, 1740-1744.

13. Alam, M.S., Sajjad, Z., Hafeez, S. & Akhter, W. J. J. O.T. P. M. A. 2011. Magnetic resonance spectroscopy in focal brain lesions. 61, 540

14. Amin, J., Sharif, M., Raza, M., Saba, T. & Rehman, A. Brain tumor classification: feature fusion. 2019 international conference on computer and information sciences (ICCIS), 2019. IEEE, 1-6

15. Anderson, M.D., Colen, R. R. & Tremont-Lukats, I. W.J.C.O R.2014. Imaging mimics of pri 19.

16. Amin J, Sharif M, Raza M, 16. Saba T, Rehman A: Brain tumor classification: feature fusion. Int Conf Comput Inf Sci. 2019, 1-6. many malignant tumors of the central nervous system (CNS). 16, 1-8. Chen, W., Zhu,

17. Alam MS, Sajjad Z, Hafeez S, Akhter W: Magnetic resonance spectroscopy in focal brain lesions. J Coll Physicians Surg Pak. 2011, 21:540-544.

18. Jesrani S, et al.: Diagnostic accuracy of magnetic resonance spectroscopy for focal brain lesions taking histopathology as gold standard. Pak J Med Sci. 2019, 29:1740-1744

Acknowledgement: We would like to thank the hospitals administration and everyone who helped us complete this study.

Disclaimer: Nil

Conflict of Interest: There is no conflict of interest.

Funding Disclosure: Nil



Open Access This article is licensed under a Creative Commons Attribution 4.0 International License, which permits use, sharing, adaptation, distribution and reproduction in any medium or format, as long as you give appropriate credit to the original author(s) and the source, provide a link to the Creative Commons licence, and indicate if changes were made. The images or other third party material in this article are included in the article's Creative Commons licence, unless indicated otherwise in a credit line to the material. If material is not included in the article's Creative Commons licence and your intended use is not permitted by statutory regulation or exceeds the permitted use, you will need to obtain permission directly from the copyright holder. To view a copy of this licence, visit <http://creativecommons.org/licenses/by/4.0/>. © The Author(s) 2022